



PATIENT
 Petunia Ehrmantraut

PRESENTING CLINICAL SIGNS
 History: Heart murmur. Collapsing episodes.
 -Pertinent lab results: Elevated Potassium/WBC.

SPECIES
 Canine

RADIOGRAPHIC FINDINGS *NOTE: Images submitted for supplemental cardiac information only.
 Normal cardiac silhouette. No obvious evidence of CHF.

BREED
 Boston Terrier Mix

ELECTROCARDIOGRAPHIC FINDINGS *Note: Single lead ECGs are evaluated as a rhythm strip.
 Morphology/MEA cannot be definitively commented on.
 A single lead ECG is available; 50mm/s, 10mm/mV. The average heart rate is 100bpm (range 46-125bpm). The rhythm is sinus in origin, with a p for every QRS complex and vice versa. The P and QRS morphologies are positive. No ectopic beats, pauses or dysrhythmias observed.
 ECG diagnosis: Suspect profound respiratory sinus arrhythmia due to high vagal tone.

SEX
 Female Spayed

AGE
 13 years

ECHOCARDIOGRAM FINDINGS
 2D, m-mode, color flow and doppler imaging is available. Diffuse thickening of mitral valve leaflets with no prolapse into the left atrial lumen. Mild eccentric mitral regurgitation with no left atrial dilation. Normal LV diameter with low normal myocardial function. The tricuspid valve appears normal with mild tricuspid regurgitation. Normal velocity. Normal right atrial and ventricular diameter and morphology indicating no overt evidence of pulmonary arterial hypertension. The pulmonic and aortic valves are normal in morphology and mobility. Normal pulmonic and aortic outflow velocities with laminar flow. No obvious aortic and trace pulmonic insufficiency. No pericardial or pleural effusion noted. No obvious cardiac masses.

WEIGHT
 40lbs

CARDIAC CHART

INTERPRETED BY
 Maggie Machen
 Lamy, DVM, DACVIM
 (Cardiology)

IMAGING PERFORMED BY
 Jenna Walsh, CVT

HOSPITAL NAME
 West Salem Animal
 Clinic

REFERRING VET
 Dr. Sirianni

INVOICE
 22875

DATE
 3/1/22

CANINE CARDIAC PARAMETERS	MR VMAX (m/s)	TR VMAX (m/s)	LA/AO (Boon method)	LA/AO (Heart Base; Swe)	FS (%)	EF (%)	EPSS (cm)
NORMAL PARAMETER	4.5-5.5	<2.7	1.3	<1.6	28-40	40-100	<0.6
PATIENT	6.0	2.3	1.2	1.2	42	75	NM
CANINE CARDIAC PARAMETERS	HR (BPM)	AV VMAX (m/s)	PV MAX (m/s)	BODY WEIGHT (kg)	LA 2D short axis Base view (cm)	LVIDd Avg; 2D and m-mode short axis (cm)	LVIDs Avg; 2D and m-mode short axis (cm)
NORMAL PARAMETER	50-100	0.7-1.7	0.7-1.6	BELOW	BELOW	BELOW	BELOW
PATIENT	80	1.4	0.7	18.1	2.2	2.7	1.5
*Normal chamber parameters expressed as a mean value (SD)				3	1.27 (5.3)	2.46 (2.46)	1.36 (5.5)
BODY WEIGHT DEPENDENT PARAMETERS				5	1.40 (4.5)	2.74 (5.2)	1.60 (4.7)
				10	1.50 (3.8)	3.27 (3.5)	2.06 (3.1)
Adapted from June Boon, Veterinary Echocardiography, 1998				15	1.83 (2.0)	3.71 (2.4)	2.43 (2.1)
Rishniw M and Hollis NE, J Vet Intern Med 2000; 14:429-435				20	2.02 (1.9)	4.14 (2.2)	2.80 (2.0)
Hansson et al, Vet Rad and Ultrasound 2002				25	2.18 (2.4)	4.48 (2.9)	3.10 (2.5)
Bonagura et al. Echocardiography: principles of interpretation, Vet				30	2.33 (3.3)	4.83 (3.9)	3.39 (3.4)



PATIENT
Petunia Ehrmantraut

Clin North Am 15:1177, 1995	35	2.48 (4.3)	5.17 (5.0)	3.69 (4.5)
	40	2.62 (5.2)	5.48 (6.1)	3.96 (5.4)
	50	2.88 (7.1)	6.07 (8.3)	4.46 (7.4)

SPECIES
Canine

BREED
Boston Terrier Mix

SEX
Female Spayed

AGE
13 years

WEIGHT
40lbs

INTERPRETED BY
Maggie Machen
Lamy, DVM, DACVIM
(Cardiology)

IMAGING PERFORMED BY
Jenna Walsh, CVT

HOSPITAL NAME
West Salem Animal
Clinic

REFERRING VET
Dr. Sirianni

INVOICE
22875

DATE
3/1/22

INTERPRETATION OF THE FINDINGS & FURTHER RECOMMENDATIONS

Chronic degenerative valve disease causing mild mitral and tricuspid regurgitation. Lack of significant left atrial enlargement indicates the current risk for complication is low. No additional issues such as systolic dysfunction or pulmonary hypertension are noted in this study.

The ECG is most consistent with a respiratory sinus arrhythmia (RSA), however correlation with respiratory phase should be confirmed (i.e., increased rate with inspiration and decrease with expiration is diagnostic for a sinus arrhythmia) as early sinus node dysfunction cannot be ruled out. High vagal tone can be a normal variant or be secondary to a variety of systemic issues such as neurologic or respiratory disease. Further evaluation via an atropine challenge and/or holter monitor may be necessary, particularly prior to anesthesia. An atropine challenge would be the next step (administer 0.04mg/kg atropine IV or IM and assess response; can administer as a pre-med prior to induction even); pending a normal response high vagal tone is diagnosed which is a benign cause. An abnormal response would indicate sinus node dysfunction, and a holter monitor and/or possible referral should be considered prior to anesthetizing.

Pending a normal atropine challenge, no cause of syncope is seen. If the atropine challenge is abnormal, further evaluation of bradycardia may be indicated, such as a holter monitor. A baseline blood pressure is also recommended.

In a dog with no significant left atrial enlargement, no cardiac medications are clearly indicated. Assessment of progression in the future will help predict long term prognosis, which is highly variable at this stage. Omega fatty acid supplementation and mild salt restriction may be of some long-term benefit. Monitor for development of a cough, labored breathing, exercise intolerance or collapse episodes.

Anesthetic risk is considered mild, pending a normal atropine challenge. Cardiac protective drug choices (opioid/benzodiazepine premedication, propofol or alfaxalone induction, isoflurane gas) are recommended. Pre-oxygenate for 5-10 minutes prior to induction. Monitor for arrhythmias, hypotension, and hypoxia both intra and post-operatively and intervene as necessary. Mild IV fluid restriction is recommended to avoid fluid overload.

PLAN

Atropine challenge is recommended. If normal, consider causes of high vagal tone that may correlate with clinical episodes. If abnormal, further evaluation is advised, such as a holter monitor.

Recommend conservative monitoring with a recheck echocardiogram in 6-12 months, sooner if any development of clinical signs



PATIENT

Petunia Ehrmantraut

SPECIES

Canine

BREED

Boston Terrier Mix

SEX

Female Spayed

AGE

13 years

WEIGHT

40lbs

INTERPRETED BY

Maggie Machen
 Lamy, DVM, DACVIM
 (Cardiology)

IMAGING PERFORMED BY

Jenna Walsh, CVT

HOSPITAL NAME

West Salem Animal
 Clinic

REFERRING VET

Dr. Sirianni

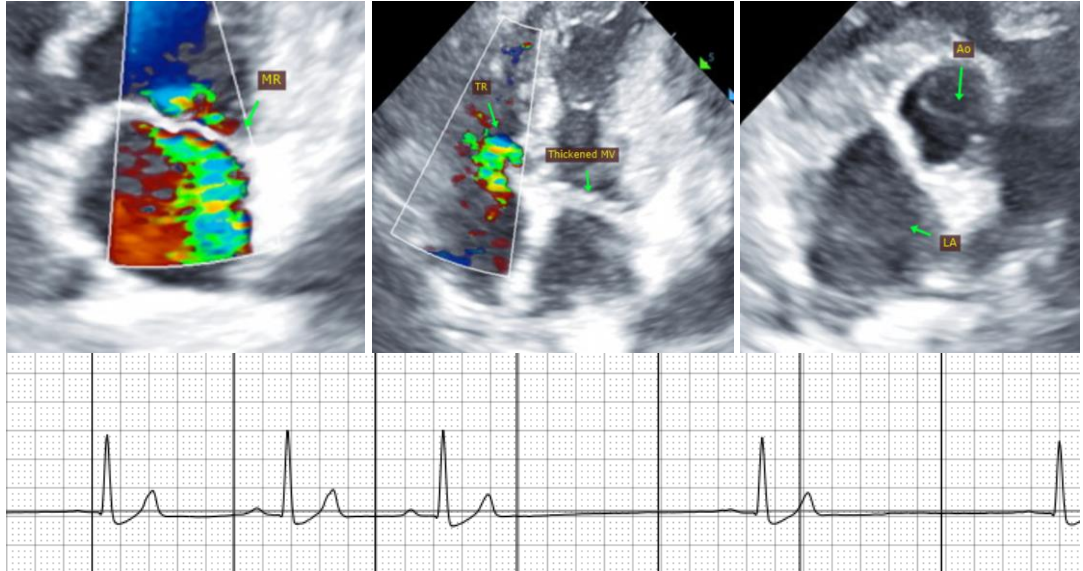
INVOICE

22875

DATE

3/1/22

IMAGES



The information and recommendations provided are based on the images presented by the referring veterinarian. No evaluation can be communicated regarding pathology that was not visible in the image/video clips provided.

Thank you for this referral. This report was generated using transcription software, and minor dictation errors may be present. If the clinical or image interpretation does not parallel your findings or if I can be of any further assistance, please contact me.

Maggie Machen Lamy, DVM
 Diplomate of the American College of Veterinary Internal Medicine (Cardiology)
 info@sonopath.com